

# Successful Treatment of More Than 100 Stones in the Intrahepatic and Extrahepatic Bile Ducts with Endoscopic Sphincterotomy Plus Papillary Balloon Dilatation Techniques

Gökhan Güngör 

Department of Gastroenterology and Hepatology, Selçuk University, Faculty of Medicine, Konya, Türkiye

**Cite this article as:** Güngör G. Successful treatment of more than 100 stones in the intrahepatic and extrahepatic bile ducts with endoscopic sphincterotomy plus papillary balloon dilatation techniques. *Diagn Interv Endosc.* 2022;1(3):75-77.

**Corresponding author:** Gökhan Güngör, E-mail: drgokhangungor@hotmail.com

**Received:** October 28, 2022 **Accepted:** December 3, 2022 **Publication date:** December 30, 2022 **DOI:** 10.5152/DiagnIntervEndosc.2022.223249



Content of this journal is licensed under a Creative Commons Attribution-NonCommercial 4.0 International License.

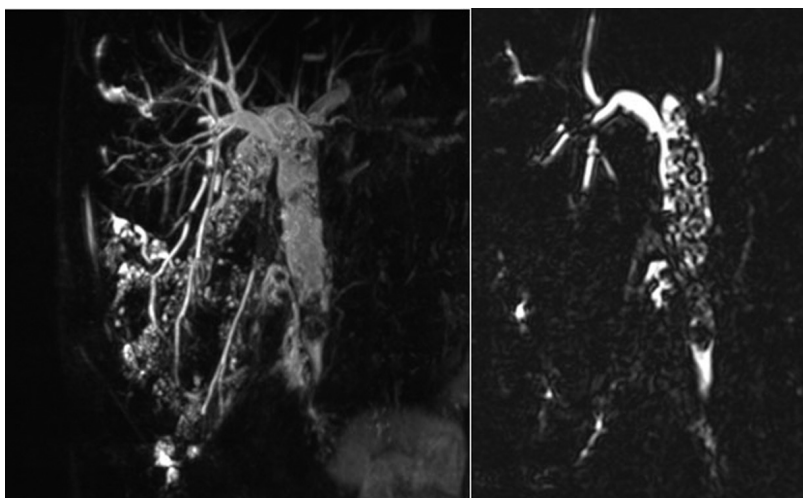
## Abstract

A 40-year-old male patient was admitted to the hospital with cholangitis. His cholestatic enzymes, bilirubin levels, and infectious markers were found to be increased. There were a lot of stones in intrahepatic and extrahepatic bile ducts on radiologic imaging. In endoscopic retrograde cholangiopancreatography, endoscopic sphincterotomy plus papillary balloon dilatation was performed, and later, intrahepatic and extrahepatic bile ducts were repeatedly cleaned with stone extraction balloon; more than 100 stones were extracted into the duodenal lumen. The patient's complaints regressed, and cholestatic enzymes and bilirubin levels decreased. Later, a second endoscopic retrograde cholangiopancreatography was performed. The residue stones that spontaneously fell from right intrahepatics to common bile duct were extracted. Endoscopic sphincterotomy plus papillary balloon dilatation provides high rates of complete stone extraction and decreases the requirement of lithotripsy and biliary stenting.

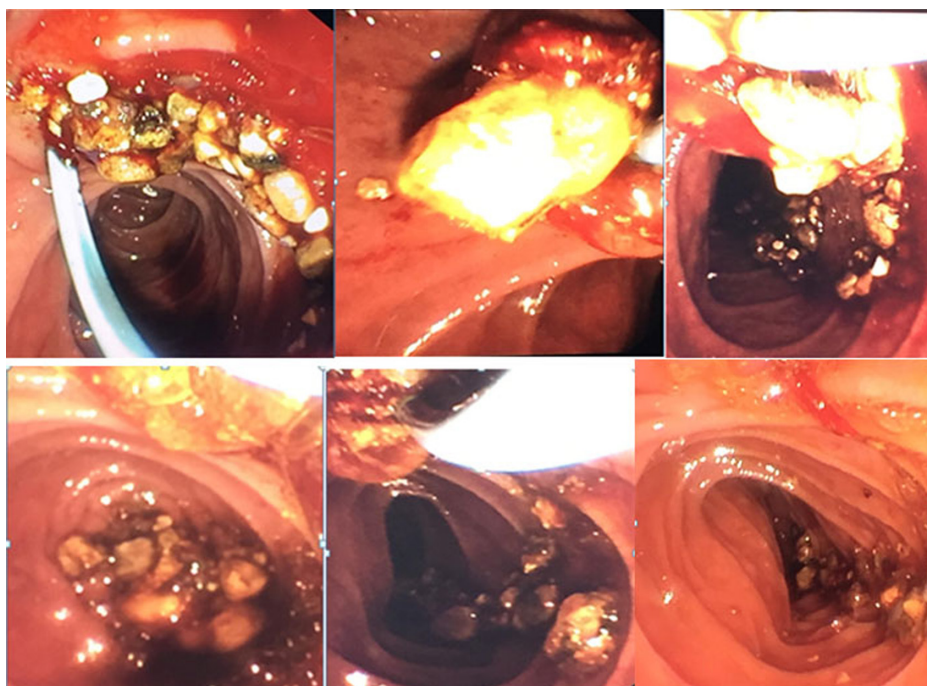
**Keywords:** Cholangitis, difficult biliary stones, endoscopic retrograde cholangiopancreatography, endoscopic sphincterotomy, endoscopic papillary balloon dilatation

## INTRODUCTION

Endoscopic retrograde cholangiopancreatography (ERCP) has an important role in the non-surgical treatment of biliary tract stones. In this way, it is possible to remove 85% of routine bile duct stones smaller than 1 cm in patients with normal biliary anatomy.<sup>1</sup> However, additional techniques and accessories may be required for the removal of larger and/or multiple difficult gallstones.<sup>2</sup> We presented a case with more than 100 stones in the bile ducts.



**Figure 1.** Magnetic resonance cholangiopancreatography shows a lot of stones.



**Figure 2.** The extraction of the multiple stones by endoscopic retrograde cholangiopancreatography.

### CASE PRESENTATION

A 40-year-old male patient was hospitalized with right upper quadrant pain, jaundice, dyspeptic symptoms, weight loss, chills, and fever. His history revealed that his gallbladder was operated. Additionally, it was understood that ERCP was performed in another center 2 weeks ago, and his doctor told him that a few stones were removed. There was no history of hepatotoxic drug, herbal medicine, and alcohol use.

On physical examination, his vital signs were stable, his body temperature was 37.6°C, and his heart-lung examination was normal. There was jaundice in sclera, skin, and mucous membranes and pain/tenderness in the upper right abdomen.

On laboratory analysis, hemoglobin, hematocrit, and platelet counts were normal. White blood cell count was 12 700 mm<sup>3</sup> (3500-10 500), C reactive protein was 72 mg/dL (<3.34), erythrocyte sedimentation rate was 64 mm/h (0-18), procalcitonin was 0.55 µg/L (<0.05), aspartate/alanine aminotransferase was 98/119 U/L (0-40/0-32), gamma-glutamyl transferase was 1143 U/L (8-61), alkaline phosphatase was 1003 U/L (40-129), total bilirubin was 5.71 mg/dL (0-1.2), direct bilirubin was 3.7 mg/dL, Ca 19-9 was 7143 U/mL (<37). Viral hepatitis serology and TORCH (Toxoplasmosis, Rubella, Cytomegalovirus, Herpes simplex) and Anti HIV panel were negative.

### MAIN POINTS

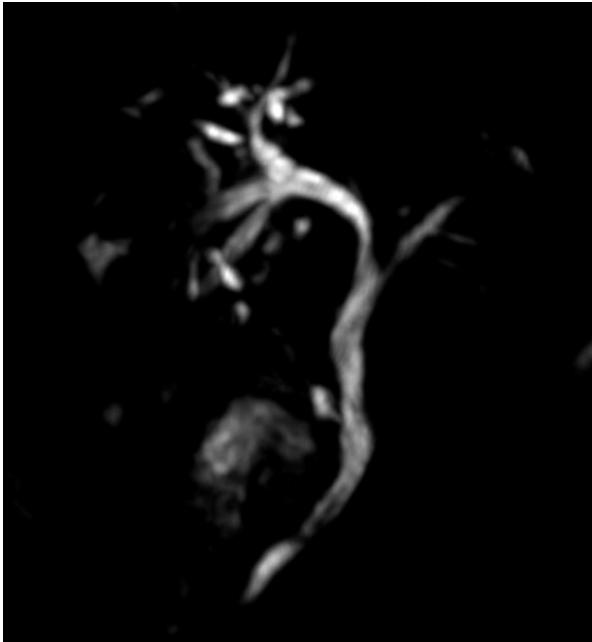
- Endoscopic retrograde cholangiopancreatography has an important role in the non-surgical treatment of biliary tract stones.
- Additional techniques and accessories may be required for the removal of larger and/or multiple difficult stones.
- Endoscopic sphincterotomy plus papillary balloon dilatation provides high rates of complete stone extraction and decreases the requirement of lithotripsy and biliary stent.

Abdominal magnetic resonance imaging and magnetic resonance cholangiopancreatography (MRCP) were performed on the patient, liver vertical size was 205 mm, gall bladder was operated, common bile duct (CBD) diameter was 11 mm, common hepatic bile duct (CHD) was 14 mm, right intrahepatic bile duct was 10 mm, left intrahepatic was minimally dilated; there were a lot of large and small stones in CBD, CHD, and intrahepatic bile ducts. There were also cholangitis signs (Figure 1).

Endoscopic retrograde cholangiopancreatography was performed on patient. The bile duct was selectively cannulated by 0.035-inch guide-wire and sphincterotome with a cutwire length of 20 mm. In cholangiogram, CBD, CHD, and intrahepatics were wide and multiple stones of sizes ranging from 3 mm to 15 mm were observed, especially in the right intrahepatic and extrahepatic bile ducts. Endoscopic sphincterotomy was performed up to its maximal share. After, 10 mm diameter balloon was inflated until the balloon waist disappeared and papillary balloon dilatation was performed for 1 minute because of difficult stones procedure. As a result of these procedures, oozing-type bleeding developed in the sphincterotomy area, but it stopped spontaneously in 8-10 seconds. Later CBD, CHD, and intrahepatic bile ducts were repeatedly cleaned with a stone extraction balloon; more than 100 stones were extracted into the duodenal lumen (Figure 2). This intervention was completed in about 45 minutes.

In the control cholangiogram, residual stone was not observed in CBD and CHD, contrast agent was rapidly discharged, but it was observed in the distal right intrahepatics. The largest of the remaining stones in the right intrahepatics were approximately 5 mm, and the sizes were decreasing to the distal in line with the lumen size.

The patient's complaints regressed, and cholestatic enzymes and bilirubin levels decreased in the follow-up. The patient was consulted with interventional radiology for percutaneous pushing of the distal right



**Figure 3.** Bile ducts after endoscopic retrograde cholangiopancreatography.

intrahepatic residual stones, but the percutaneous intervention was not recommended and the patient was followed up closely. Any cholangitis attack or cholestatic enzyme and bilirubin elevation did not develop in the follow-ups.

Later, repeat ERCP was performed after 6 months. It was observed that the previous residual stones spontaneously fell from the right intrahepatic to the CBD. These residual stones were completely cleaned with extraction balloon from choledoc. The current MRCP imaging of the patient was given in Figure 3.

## DISCUSSION

Acute cholangitis is a life-threatening infection that results from a biliary tree obstruction. Early diagnosis and treatment is the most important topic to reduce mortality and morbidity. Even though fluid-electrolyte replacement and broad-spectrum antibiotics are effective in the treatment, the most important approach is to provide biliary drainage with ERCP or percutaneous transhepatic cholangiography.

In our patient, there were multiple stones that completely fill the right intrahepatics, CHD, and CBD. We successfully treated both cholangitis and these stones with endoscopic sphincterotomy plus papillary balloon dilatation techniques.

Endoscopic retrograde cholangiopancreatography is an important diagnostic and therapeutic method for biliary tract pathologies. Especially, endoscopic sphincterotomy plus papillary balloon dilatation is an effective method for the treatment of large and/or multiple stones in ERCP. This technique provides high rates of complete stone extraction and decreases the requirement of lithotripsy and biliary stent.<sup>3-5</sup> The effectiveness of balloon dilation is related to balloon size, the pressure of inflation, and ballooning time.<sup>6</sup> It was reported that the rate of stone

removal was higher, the use of lithotripsy was lower, and complication rates were similar with a 10-mm wide balloon compared to an 8-mm wide balloon.<sup>7</sup> In our patient, the CBD diameter was 11 mm. The papillary balloon dilatation was performed with a 10-mm diameter balloon, considering that a large number of stones in distal bile ducts could be squeezed between the wall of the choledoc and the balloon and cause perforation or bleeding. Even so, there was minor self-limiting bleeding. The balloon waist disappearance approach during inflation in clinical practice is a widely used method.<sup>8,9</sup> Although there is no general consensus, European Society of Gastrointestinal Endoscopy guidelines recommended balloon dilation time of more than 1 minute.<sup>10</sup>

This case was an interesting experience for us. We searched the literature and did not encounter an endoscopic procedure in which so many stones were extracted. In this patient, if these stones could not be removed endoscopically, hepatobiliary surgery might have been required, and even cholangitis attacks and secondary biliary cirrhosis might have developed.

**Informed Consent:** Written informed consent was obtained from the patient

**Peer-review:** Externally peer-reviewed.

**Declaration of Interests:** The author declare that they have no competing interest.

**Funding:** The author declared that this study has received no financial support.

## REFERENCES

- Lauri A, Horton RC, Davidson BR, Burroughs AK, Dooley JS. Endoscopic extraction of bile duct stones: management related to stone size. *Gut*. 1993;34(12):1718-1721. [\[CrossRef\]](#)
- Ersöz G, Tekesin O, Ozutemiz AO, Günsar F. Biliary sphincterotomy plus dilation with a large balloon for bile duct stones that are difficult to extract. *Gastrointest Endosc*. 2003;57(2):156-159. [\[CrossRef\]](#)
- Heo JH, Kang DH, Jung HJ, et al. Endoscopic sphincterotomy plus large-balloon dilation versus endoscopic sphincterotomy for removal of bile-duct stones. *Gastrointest Endosc*. 2007;66(4):720-726. [\[CrossRef\]](#)
- Rosa B, Ribeiro PM, Rebelo A, Pinto Correia A, Cotter J. Endoscopic papillary balloon dilation after sphincterotomy for difficult choledocholithiasis: a case-controlled study. *World J Gastrointest Endosc*. 2013;16(5):211-218. [\[CrossRef\]](#)
- Aujla UI, Ladep N, Dwyer L, Hood S, Stern N, Sturgess R. Endoscopic papillary large balloon dilatation with sphincterotomy is safe and effective for biliary stone removal independent of timing and size of sphincterotomy. *World J Gastroenterol*. 2017;23(48):8597-8604. [\[CrossRef\]](#)
- Fujisawa T, Kagawa K, Hisatomi K, Kubota K, Nakajima A, Matsuhashi N. Is endoscopic papillary balloon dilatation really a risk factor for post-ERCP pancreatitis? *World J Gastroenterol*. 2016;22(26):5909-5916. [\[CrossRef\]](#)
- Akiyama D, Hamada T, Isayama H, et al. Superiority of 10-mm-wide balloon over 8-mm-wide balloon in papillary dilation for bile duct stones: a matched cohort study. *Saudi J Gastroenterol*. 2015;21(4):213-219. [\[CrossRef\]](#)
- Jeong S, Ki SH, Lee DH, et al. Endoscopic large-balloon sphincteroplasty without preceding sphincterotomy for the removal of large bile duct stones: a preliminary study. *Gastrointest Endosc*. 2009;70(5):915-922. [\[CrossRef\]](#)
- Kogure H, Tsujino T, Isayama H, et al. Short- and long-term outcomes of endoscopic papillary large balloon dilation with or without sphincterotomy for removal of large bile duct stones. *Scand J Gastroenterol*. 2014;49(1):121-128. [\[CrossRef\]](#)
- Dumonceau JM, Andriulli A, Deviere J, et al. European Society of Gastrointestinal Endoscopy (ESGE) Guideline: prophylaxis of post-ERCP pancreatitis. *Endoscopy*. 2010;42(6):503-515. [\[CrossRef\]](#)